



Available online at www.sciencedirect.com

SCIENCE @ DIRECT®

Schizophrenia Research xx (2005) xxx–xxx

SCHIZOPHRENIA
RESEARCH

www.elsevier.com/locate/schres

Paracingulate sulcus morphology and fMRI activation detection in schizophrenia patients

Eric Artiges^{a,d}, Catherine Martelli^a, Lionel Naccache^b, David Bartrés-Faz^{a,e},
Jean-Bernard LeProvost^a, Armelle Viard^a, Marie-Laure Paillère-Martinot^{a,c},
Stanislas Dehaene^b, Jean-Luc Martinot^{a,*}

^a INSERM-CEA Research Unit URM 02–05 “Neuroimaging in Psychiatry”, National Institute for Health and Medical Research (INSERM) and Atomic Energy Commission (CEA), IFR49, Frédéric Joliot hospital department, Orsay, France

^b INSERM-CEA Research Unit U562 «Cognitive Neuroimaging», IFR49, Frédéric Joliot hospital department, Orsay, France

^c AP-HP, Psychiatry department, A. Chenevier and H. Mondor Hospitals, Créteil, France

^d Psychiatry department, Orsay hospital, Orsay, France

^e IDIBAPS; department of psychiatry and clinical psychobiology Barcelona University, Barcelona, Spain

Received 8 June 2005; received in revised form 17 October 2005; accepted 29 October 2005

Abstract

Objective: Altered anterior cingulate cortex activity has been consistently detected by functional imaging in schizophrenia patients. In the present study, we hypothesized that the detection of such local hypoactivity varies when the subjects’ local gyrification is monitored. Using a group-statistical approach, we investigated whether the presence or absence of a paracingulate sulcus (PCS) does influence the detection of the activation patterns in the cognitive division of the anterior cingulate cortex (ACcd).

Method: fMRI data were acquired using an event-related paradigm during a task involving both priming and interference between stimuli. In the fMRI dataset collected from 13 schizophrenia patients and 16 healthy subjects, subgroups were defined according to the presence or absence of a PCS. Regional activations during interference between stimuli were examined in the ACcd of each hemisphere, using for each region of interest both voxel-based random-effects and non-parametric analyses.

Results: ACcd activation was left-sided in healthy subjects with a PCS, and right-sided in healthy subjects devoid of a PCS. ACcd activations were detected bilaterally in schizophrenia patients with a PCS, whereas left ACcd was deactivated in patients without a PCS. Subgroup comparisons revealed no difference between healthy subjects with a PCS and patients with a PCS, whereas in the subgroups devoid of PCS, the patients exhibited a bilateral ACcd hypoactivation relative to healthy subjects.

Conclusions: PCS presence or absence influences the detection of ACcd activations in group-analysis of schizophrenia patients.

© 2005 Elsevier B.V. All rights reserved.

Keywords: Schizophrenia; Functional MRI; Paracingulate sulcus; Cingulate; Gyrification

* Corresponding author. INSERM-CEA ERM 0205, Service Hospitalier Frédéric Joliot, 4 Place du Général Leclerc, 91401 Orsay Cedex, France. Tel.: +33 1 69 86 77 57; fax: +33 1 69 86 78 10.

E-mail address: jlmartinot@cea.fr (J.-L. Martinot).

0920-9964/\$ - see front matter © 2005 Elsevier B.V. All rights reserved.

doi:10.1016/j.schres.2005.10.022

1. Introduction

Altered anterior cingulate cortex activity has been consistently detected by functional imaging studies in schizophrenia patients, but the relationship with anatomical characteristics remains poorly understood. Most functional deficits reported in the literature were observed with voxel-based group-analyses that ignored inter-individual morphological variations. Moreover, the impact of local structure variations on the detection of activations using such group-analysis procedure is fairly unknown. Notably, a lack of leftward paracingulate sulcus (PCS) asymmetry has been reported in a significant proportion of schizophrenia patients (Le Provost et al., 2003; Yucel et al., 2002b).

Although the cingulate gyrus forms a single and continuous structure, it is functionally heterogeneous. It includes a dorsal subregion or “cognitive division” (Bush et al., 2000) which has been related to the monitoring of conflicts, detection of errors, response to task difficulty, and attention for action (Botvinick et al., 2001). Neuroimaging studies examining these cognitive functions, such as detection of conflicts between stimuli or Stroop-like tasks (Carter et al., 2001, 1997; Dehaene et al., 2003; Heckers et al., 2004; Morey et al., 2005; Yucel et al., 2003), as well as word-recall and working memory tasks (Artiges et al., 2000b; Crespo-Facorro et al., 1999; Haznedar et al., 2004; Hofer et al., 2003; Nohara et al., 2000), have reported a deficit in activation of the anterior cingulate “cognitive division” (ACCd) in schizophrenia patients.

The variations in ACC folding may contribute to the functional differences between schizophrenia patients and healthy subjects. Indeed, using positron tomography in small samples, Yucel et al. (2002a) have reported both limbic and paralimbic ACC activations during a Stroop task in healthy subjects, whereas only paralimbic ACC activations were detected in schizophrenia patients having a PCS. The influence of this variation in ACC gyrification on the functional neuroimaging results needs to be replicated and extended by independent samples. Specifically, since most functional deficits reported in the literature were derived from voxel-based group-analyses, the influence of ACC gyrification patterns on this procedure should be considered. We set out to complement and reanalyze the data from a previous functional magnetic resonance imaging (fMRI) study (Dehaene et al., 2003) that

detected group hypoactivation in the left ACCd of schizophrenia patients compared to healthy subjects. Using a voxel-based random-effects group analysis, we tested the hypothesis that a local folding particularity such as the presence or absence of a PCS influences the detection of patients ACCd hypoactivity.

2. Methods

2.1. Subjects

Fifteen patients with schizophrenia and twenty-one age-matched healthy subjects participated in the study. All subjects were right-handed males and native speakers. The two groups were comparable for age ($t=0.83$; $p=0.41$) and education level ($t=1.41$; $p=0.17$). Subjects' demographic, patients' ratings and treatments are summarized in Table 1. Exclusion criteria included alcohol or other drug abuse, depression, neurological disease, and impaired visual acuity. Healthy subjects were excluded if they fulfilled any criteria for current and lifetime psychiatric disorder (DSM-IV) assessed by a review of medical history and an interview by a senior psychiatrist (either by JLM, EA, CM, or MLPM).

Patients met DSM-IV criteria for schizophrenia and were recruited from consecutive admissions to psychiatric departments of the Assistance Publique, Hôpitaux de Paris. Four patients had a residual type, three an undifferentiated type, seven a paranoid type and one had a schizoaffective disorder. All had a chronic course and were stabilized with usual dosages of an atypical antipsychotic treatment. None received antidepressants, lithium, or electro-convulsive therapy at the time of testing. Patients were rated with the Scale for the Assessment of Negative Symptoms (SANS), the Scale for the Assessment of Positive Symptoms (SAPS), and the Positive and Negative Syndrome Scale (PANSS).

The study was approved by the regional ethical committee for Biomedical Research (Bicêtre Hospital), and each subject had given written informed consent prior to the experiment.

2.2. Paracingulate sulcus identification

Four subgroups, two in each group, were defined by two independent experienced raters (JBLP and

Table 1

Subjects' demographic and patients' treatments and rating scores with the Scale for the Assessment of Negative Symptoms (SANS), the Scale for the Assessment of Positive Symptoms (SAPS), and the Positive and Negative Syndrome Scale (PANSS)

Group	Schizophrenia patients			Healthy subjects		
	Whole group	With PCS	Without PCS	Whole group	With PCS	Without PCS
Number of subjects	15 ^a	5	8	21 ^a	11	5
Mean age (range)	28.1 (19–36)	30.2 (23–36)	27.5 (19–31)	27 (18–44)	25.5 (18–36)	27.2 (18–44)
Education (years after primary school)	7.1 (4–12)	8.4 (6–12)	6.3 (4–10)	8.3 (5–14)	8.1 (5–12)	8.8 (6–14)
Negative PANSS	23 ± 7	21 ± 9	24 ± 5			
Positive PANSS	14 ± 6	14 ± 7	14 ± 6			
General psychopathology	35 ± 9	35 ± 12	34 ± 8			
SANS	49 ± 18	47 ± 8	45 ± 14			
SAPS	20 ± 17	17 ± 17	21 ± 15			
Treatment	<i>n</i>	<i>n</i> (dosage mg/day)				
Amisulpride	4	1 (400)				
Olanzapine	4	2 (10; 10)				
Risperidone	3	2 (2; 6)				
Clozapine	2	0				

^a fMRI data were available only in 13 patients and 16 healthy subjects.

DBF; reliability: $\kappa \geq 0.9$), according to the presence or absence of a PCS. The PCS extends dorsally and parallel to the cingulate sulcus, lying in the medial walls of the frontal lobes. Measurements were made using the method for PCS pattern description as defined by Yucel et al. in healthy adults (Yucel et al., 2001). The origin of the PCS was defined as the point where the sulcus extends backward, from a coronal plane parallel to the line through the anterior commissure, and perpendicular to the line through the anterior and posterior commissures. The PCS was classified as 'prominent' if the sulcus extended at least 40 mm and exhibited no more than 20 mm of interruptions between its origin and a coronal plane passing through the anterior commissure. If interruptions exceeded 20 mm and the length was at least 20 mm, the paracingulate sulcus was classified as 'present'. PCS was considered as present when it was classified as 'prominent' or 'present'. Finally, when no sulcus parallel to the cingulate sulcus could be found or was less than 20 mm in length, it was classified as 'absent'.

2.3. Stimuli

The event-related priming paradigm used in the present study, has previously been described in detail (Dehaene et al., 2003). The task aimed to study cerebral activations during conscious and subliminal

conflict induced by task-irrelevant primes. As subliminal conflict did not reveal differences between healthy subjects and patients with schizophrenia, we only report here the fMRI data from trials where the prime was unmasked, thus yielding a conscious Stroop-like interference.

The stimulus set consisted of 2 sets of 32 randomly intermixed pairs of prime and target numbers, each consisting of the numbers 1, 4, 6, and 9 written in either words or Arabic format (Fig. 1). Subjects were asked to neglect the prime and to compare each target number with the number 5 by pressing, as fast as possible, the right-hand key for numbers larger than 5, and the left-hand key for numbers smaller than 5. Each stimulus could be congruent or incongruent whether or not the prime and target agreed.

Each trial included a first blank screen of 71 ms, a prime of 43 ms, a second blank screen of 71 ms, a target of 200 ms, followed by a blank screen of 11.615 s. Prior to each trial, a warning signal (a rectangle surrounding the stimulus position) appeared for 2 s. The total duration of each trial was 14 s.

2.4. MRI procedure

An event-related functional MRI design was used. Stimuli were presented through mirror glasses and an active matrix video projector. Stimulus onset was synchronized with the acquisition of the first of 7

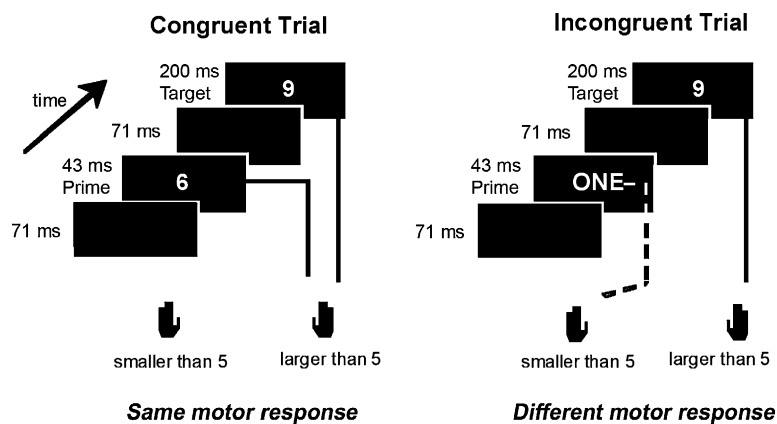


Fig. 1. Experimental paradigm. Subjects compared a 200-ms target number to the fixed number 5. Each target was preceded by a fast presentation of another number that served as a prime. Subjects were asked to neglect the prime and to compare each target number with 5 by pressing, as fast as possible, the right-hand key for numbers larger than 5, and the left-hand key for numbers smaller than 5. Stimuli could be congruent or incongruent whether or not the prime and target agreed.

volumes (one volume every 2 s) for each trial. Two runs of 32 randomized trials plus one initial training trial (which was later discarded) were presented. A total of 462 volumes were acquired for the two runs (2 runs \times (32+1) trials \times 7 volumes) for a total duration of 15 min 24 s. We used a gradient-echo echo-planar imaging sequence sensitive to brain oxygen-level dependent (BOLD) contrast (18 contiguous axial slices, 6 mm thickness, TR/TE=2000/60 ms, FOV 24 cm, 64×64 matrix, voxel size $3.75 \times 3.75 \times 6$ mm) on a 1.5-T whole-body system (Signa, General Electric).

Anatomical images were acquired using a 3D fast gradient-echo inversion-preparation sequence (124 contiguous axial slices, 1.2 mm thickness, inversion time=600 ms, TE=2.2 ms, FOV 24 cm, Flip 10° , 256×192 matrix, voxel size $0.9375 \times 0.9375 \times 1.2$ mm).

2.5. Statistical analysis

2.5.1. Behavioral data

Median reaction time (RT) and accuracy (error rate) data were analyzed using a repeated-measure analysis of variance (ANOVA) with the group (patients with schizophrenia and healthy subjects) and the PCS status (with and without a PCS) as between-subject factors, and the prime-target relation (congruent and incongruent) as within-subject factor.

2.5.2. fMRI data

The initial 7 fMRI volumes of each run, corresponding to the first trial were discarded, leaving 224 image volumes in each run. Using Statistical Parametric Mapping (SPM99) software (<http://www.fil.ion.ucl.ac.uk/spm/>), images were corrected for subject motion and slice acquisition delay, normalized into standard stereotaxic space using a linear transform calculated on the anatomical images, and smoothed using a Gaussian spatial filter (FWHM: 5 mm). For each subject and each event type, the signal was modeled as a linear combination, of a standard haemodynamic response function and its temporal derivative, allowing for different delays across brain regions. Event types were defined by a combination of the following factors: response hand, prime-target relation (congruent, incongruent), and notation identity (prime and target in same or different notation). Only correctly responded trials were included in the individual analyses.

In order to assess the incidence of PCS variations on ACC activations, we focused on the cognitive division of the anterior cingulate (ACcd) (Bush et al., 2000) engaged in the task in healthy subjects. In order to define two regions of interest (ROI) within the ACcd, one in each hemisphere, we performed a preliminary random-effect analysis in healthy subjects. We applied the one sample *t*-test procedure in SPM99 on the statistical parametric maps obtained in each subject from the contrast between incongruent

and congruent trials ($p < 0.005$ for voxel level, uncorrected). Using the Anatomist software (<http://brainvisa.info/>), we drew the ROIs symmetrically according to the main clusters of activation detected within the ACcd in healthy subjects (Fig. 2).

Two analyses were performed afterwards. First, using these ROIs as masks, a random-effect analysis (one-way ANOVA in SPM99) was performed on the statistical parametric maps of the relevant contrast (incongruent *minus* congruent). The four subgroups (healthy subjects with PCS, healthy subjects without PCS, schizophrenia subjects with PCS and schizophrenia subjects without PCS) were used as be-

tween-group factor. Significance threshold was set at 0.05 for voxel level, corrected for multiple comparisons.

Second, using the Marsbar toolbox (Brett et al., 2002) of SPM99, we extracted the mean activation values within each ROI (left and right ACcd) for all subjects. In order to compare the four subgroups, non-parametric Kruskal–Wallis tests were performed on those values (left and right ACcd), and on the difference between left and right ACcd activation as asymmetry index. Post-hoc Mann and Whitney rank U tests were used to compare subgroups when Kruskal–Wallis tests were significant.

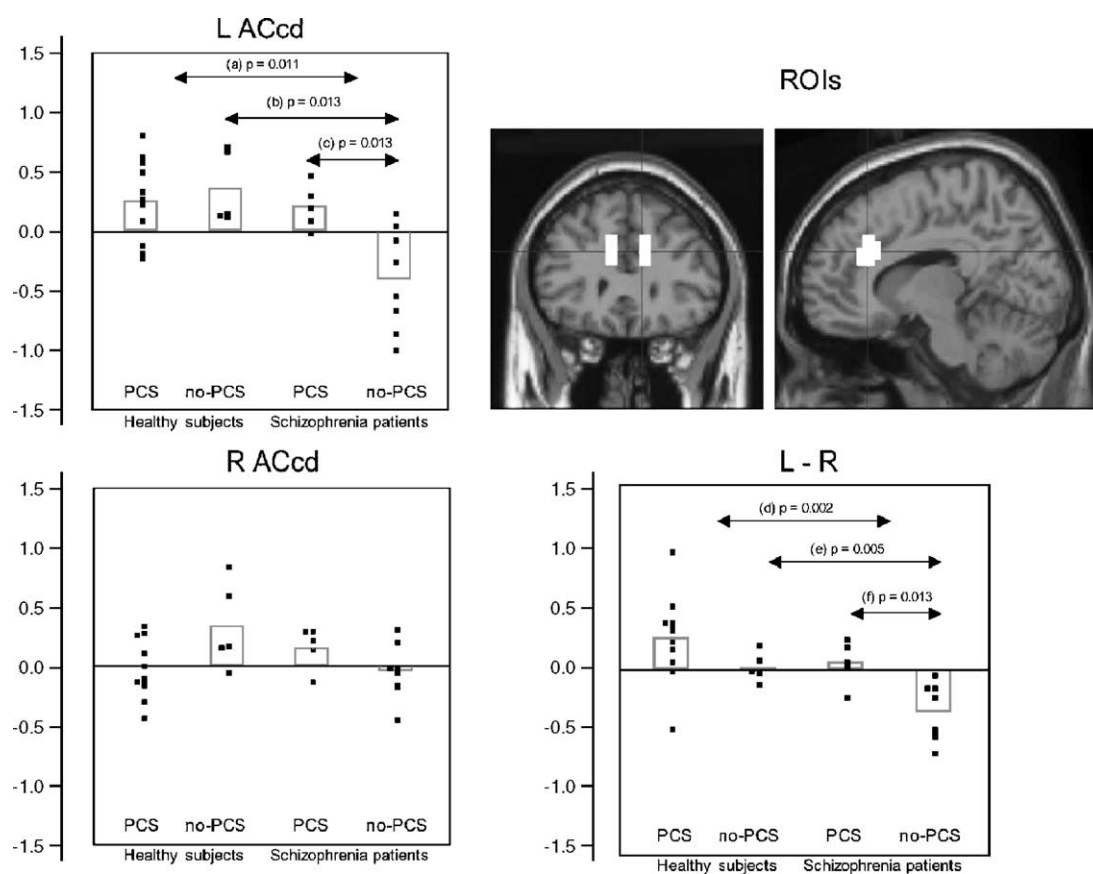


Fig. 2. Adjusted mean fMRI values for the incongruent > congruent comparison, obtained from each region of interest (ROI) and from the asymmetry index in each subgroup. L ACcd: left anterior cingulate cognitive division; R ACcd: right anterior cingulate cognitive division; L–R: asymmetry index (left–right). PCS: paracingulate sulcus. Post-hoc Mann and Whitney U results: (a) Healthy subjects versus schizophrenia patients: $U=46$, $z=-2.54$, $p=0.011$. (b) No-PCS healthy subjects versus no-PCS schizophrenia patients: $U=3$, $z=-2.49$, $p=0.013$. (c) PCS schizophrenia patients versus no-PCS schizophrenia patients: $U=3$, $z=-2.49$, $p=0.013$. (d) Healthy subjects versus schizophrenia patients: $U=25$, $z=-3.03$, $p=0.002$. (e) No-PCS healthy subjects versus no-PCS schizophrenia patients: $U=1$, $z=-2.78$, $p=0.005$. (f) PCS schizophrenia patients versus no-PCS schizophrenia patients: $U=3$, $z=-2.49$, $p=0.013$.

3. Results

3.1. Behavioral results

Patients exhibited significantly lower median reaction times (RT) than healthy subjects (665 versus 539 ms, $F(1,32)=10.31$, $p=0.003$). No effect for the PCS status and the prime-target relation was observed. However, there was a group by prime-target relation interaction ($F(1,32)=6.98$, $p=0.012$), indicating that healthy subjects were faster on congruent trials than on incongruent trials (522 versus 556 ms, $F(1,20)=59.44$, $p<0.0001$), while no difference was found for patients (668 versus 662 ms, $F(1,14)=0.16$, $p=0.69$). No other significant interactions were detected.

The error rate was slightly and non-significantly higher in patients than in controls (3.7% versus 2.4% errors). No significant differences were observed between subgroups or conditions. (patients without a PCS: 4.2%; patients with a PCS 3%; healthy subjects without a PCS: 3%; healthy subjects with a PCS 2.1%).

3.2. Paracingulate ratings

Behavioral data were available for all subjects. With regard to the fMRI data only 13 patients and 16 healthy subjects were included in the analysis, due to motion artifacts and other technical difficulties. Inspection of anatomical MR T1 images detected eight patients without PCS, five with at least one PCS (2 left, 2 right, and one bilateral), five healthy subjects without PCS, and eleven healthy subjects with at least one PCS (6 left, 3 right, and 2 bilateral). The subgroups were comparable for age (Kruskal–Wallis test: $H=3.31$; $p=0.35$) and for education level ($H=3.44$; $p=0.33$).

Both subgroups of patients were treated with usual dosages of an atypical antipsychotic (Table 1).

3.3. fMRI results

3.3.1. Statistical parametric results (Table 2)

In healthy subjects, the incongruent *minus* congruent comparison revealed three peaks of activation within the ACC cognitive division (ACcd), two left-sided and one right-sided. Variations in the distribution of lateralization were detected according to the presence or absence of PCS. Healthy subjects with PCS did activate the left ACcd whereas those without PCS did activate the right ACcd.

In schizophrenia patients, no ACcd activation was detected in the group as a whole, and we observed two clearly differentiated patterns of ACcd activation according to the presence or absence of PCS: in patients with PCS,

ACcd activations were detected bilaterally, whereas the left ACcd deactivated in those without PCS.

The group comparison revealed a hypoactivation in the left ACcd in schizophrenia patients as compared to healthy subjects. No difference was detected in the right ACcd.

The comparison of PCS subgroups within healthy subjects showed that the right ACcd was more activated in the subgroup devoid of PCS than in the subgroup with PCS. In schizophrenia patients, the left ACcd was more activated in the subgroup with PCS than in the subgroup devoid of PCS.

No difference between healthy subjects with PCS and patients with PCS was observed, whereas in the subgroups devoid of PCS, schizophrenia patients exhibited a bilateral ACcd hypoactivation relative to healthy controls.

3.3.2. Non-parametric results (Fig. 2)

Kruskal–Wallis tests applied for subgroups comparison on the mean activation values obtained within each ROI, were significant in the left ACcd ($H=11.33$; $p=0.010$) and for the asymmetry index ($H=16.06$; $p=0.001$), but not in the right ACcd ($H=4.68$; $p=0.197$). As Fig. 2 shows, healthy subjects with and without PCS and schizophrenia patients with PCS showed higher left ACcd activation compared to schizophrenia patients without PCS. Plots and post-hoc Mann and Whitney *U* tests' *p* values are represented in Fig. 2.

4. Discussion

These results, obtained with a voxel-based random-effects group analysis, indicate that a morphological feature such as the presence or absence of a PCS modifies the detection of schizophrenia patients' anterior cingulate activity. This study confirms that patients' local gyrification can influence functional MRI results. The effects of gyrification on cerebral activations were not examined in most preceding functional brain imaging studies on schizophrenia related to the anterior cingulate cortex (Artiges et al., 2000b; Carter et al., 2001, 1997; Crespo-Facorro et al., 1999; Dehaene et al., 2003; Haznedar et al., 2004; Hofer et al., 2003; Kerns et al., 2005; Morey et al., 2005; Nohara et al., 2000).

Here, the results collected from usual group-analysis methods can be modulated when subjects' gyrification is taken into account. This has been verified using three complementary results. First, the results *within* each subgroup indicate that ACcd

activation depends not only upon the group condition (patient, healthy), but also on the PCS pattern. Indeed, only the subgroup of patients without a PCS displays bilateral absence of ACCd activation, whereas in all other subgroups at least one ACCd does activate (Table 2). Second, comparisons *between* subgroups reveal significant ACCd hypoactivation in patients without PCS. Third, the asymmetry index suggests that the gyrification factor has an influence on the functional laterality.

These findings confirm a previous report (Yucel et al., 2002a), showing deficits in paralimbic activation in patients without a PCS. Using individual analyses in order to show PCS morphology effect on H₂¹⁵O PETscan activations during a Stroop task in five healthy and six schizophrenia subjects, Yucel et al. reported that patients without a PCS displayed no activation across the entire ACC. In a recent study using a multi-source interference task in order to activate the dorsal ACC, Heckers et al. (2004) reported a lack of dorsal ACC activation in some schizophrenia patients, and individual analyses revealed differentiated activations' patterns according to the PCS status, but not according to the diagnosis. Subgroup analyses taking into account the PCS status were not conducted. In those reports, individual analysis was used because the effects of stereotaxic

normalization and of individual variability can lead to failing to detect activations, notably when pooling data from small samples. Here, we aimed at showing that a usual group analysis could yield analogous results. We performed a random-effect group analysis accounting for the individual variability of fMRI volumes, by forming subgroups defined on the PCS presence. The random-effect analysis is based on the reanalysis of statistical parametric maps obtained from each subject's fMRI images. Although this procedure is conservative (Friston et al., 1999), our results must be regarded as observatory, due to the small size of each subgroup. Still, activation difference between patient subgroups with or without PCS does not mean that individually, each patient devoid of PCS did hypoactivate (Fig. 2).

The statistical parametric maps showed the activated areas, but precluded the determination of a laterality index. Hence, ACCd asymmetry was investigated with complementary statistical methods. The asymmetry index was obtained with the Marsbar toolbox (Brett et al., 2002) which estimates the mean activation value in each region of interest, and non-parametric tests were applied on the mean activation values. This method suggests a prominent asymmetry of ACCd activation in the patient subgroup devoid of PCS, which was more rightward lateralized than all

Table 2

Results of the one-way ANOVA comparing the different subgroups within the cognitive division of the anterior cingulate (ACCd), for the incongruent versus congruent comparison

Group	PCS status	Left ACCd					Right ACCd				
		Talairach coordinates			Z score	p	Talairach coordinates			Z score	p
		x	y	z			x	y	z		
Healthy subjects	All	-12	32	36	3.44	0.012	12	28	20	2.99	0.034
		-12	28	24	2.90	0.050					
Healthy subjects	PCS	-12	28	36	3.26	0.02					
Healthy subjects	No-PCS						12	28	24	3.63	0.005
Healthy subjects	No-PCS>PCS						16	28	24	3.70	0.004
Schizophrenia patients	PCS	-16	32	28	2.94	0.046	16	28	20	2.91	0.041
Schizophrenia patients	No-PCS	-12	28	24	3.72	0.005 ^a					
Schizophrenia patients	PCS>no-PCS	-16	32	28	4.15	0.001					
Healthy subjects>Schizophrenia patients	All	-12	28	24	3.62	0.007					
Healthy subjects>Schizophrenia patients	No-PCS	-12	28	24	3.37	0.004	16	28	24	3.05	0.029
Healthy subjects>Schizophrenia patients	PCS>no-PCS	-12	28	28	4.23	0.001					

Only the significant results are exposed. The non-significant results were deleted.

Talairach coordinates: Talairach and Tournoux, 1988.

Significant thresholds were 0.05 for voxel level corrected for multiple comparisons.

^a Deactivation.

other subgroups. Healthy subjects appeared to be more leftward lateralized than patients, in line with previous reports (Artiges et al., 2000a; Berlim et al., 2003; Crow, 1997; Sommer et al., 2001).

The following limitations can be highlighted. First, the main purpose of the study was to test if the presence or absence of a PCS did influence the detection of patients' ACCd hypoactivity at a group level, using an averaged image analysis approach. All possible PCS morphological cases (left, right, and bilateral) have not been tested with a subgroup approach, given the small numbers in each case. Also, the smallness of the subgroups precluded the investigation of a relationship between regional activation and cognitive performance. Inasmuch as one would not necessarily expect an effect in RT to be related in a direct way to the BOLD signal as they measure different processes, we did not intend to generalize on a putative structure–function relationship.

Second, given that the anterior cingulate is involved in a number of psychiatric disorders, including schizophrenia, unipolar depression, autism, post-traumatic stress disorder, and OCD, present results cannot be related specifically to schizophrenia.

Third, psychopharmacological effects of antipsychotic treatments, whether typical or atypical, were reported as a factor that could influence activations during a cognitive task (Sharma, 2003), and could constitute a limitation for the interpretation of the results (Yucel et al., 2002a). However, since both subgroups of patients were stabilized with usual dosages of atypical antipsychotics (Table 1), the medication status is unlikely to account for the differences of activation between subgroups of patients.

Fourth, in order to focus on the hypothesis and to constrain the number of statistical tests, the present analysis was limited to the ACCd part engaged by the task in healthy subjects, thus allowing hypothesis-driven corrected statistics. A functional analysis on the whole brain was inadequate because of the small sample size, but could be a future issue to investigate. Indeed, according to the Van Essen model (Van Essen, 1997), the absence of a PCS could be the consequence of a weaker local connectivity within the paralimbic cortex (Brodmann's area 32), that may impair the activity of distant regions (Fletcher et al., 1999; Kim et al., 2003; Nahas et al., 2003; Spence et al., 2000). In addition, the links between regional activations and

gyrification were not examined in other cortical regions, whereas differences in cortical complexity is probable in schizophrenia patients (Wiegand et al., 2005).

In conclusion, the present study reports the influence of PCS presence on fMRI group-analysis of schizophrenia patients, and suggests that such effect of gyrification deserves to be examined in other cortical regions such as the posterior branches of the superior temporal sulcus whose physiologic variability is marked (Ono et al., 1990).

Acknowledgments

This research was in part supported by a French research ministry grant "ACI cognitive". Catherine Martelli and Jean-Bernard LeProvost were supported by the "Fondation pour la Recherche Médicale". David Bartrés-Faz was supported by the Spanish Ministry of Science and Technology (Ramón y Cajal program) and the French Institut National de la Santé et de la Recherche Médicale (INSERM Postes Verts). The authors thank Drs F. Schürhoff and C. Recasens for allowing enrollment of some patient. J.F. Brouillet and Dr M. Wessa are thanked for their comments.

References

- Artiges, E., Martinot, J.L., Verdys, M., Attar-Levy, D., Mazoyer, B., Tzourio, N., Giraud, M.J., Paillere-Martinot, M.L., 2000a. Altered hemispheric functional dominance during word generation in negative schizophrenia. *Schizophr. Bull.* 26, 709–721.
- Artiges, E., Salame, P., Recasens, C., Poline, J.B., Attar-Levy, D., De La Raillere, A., Paillere-Martinot, M.L., Danion, J.M., Martinot, J.L., 2000b. Working memory control in patients with schizophrenia: a PET study during a random number generation task. *Am. J. Psychiatry* 157, 1517–1519.
- Berlim, M.T., Matvevi, B.S., Belmonte-de-Abreu, P., Crow, T.J., 2003. The etiology of schizophrenia and the origin of language: overview of a theory. *Compr. Psychiatry* 44, 7–14.
- Botvinick, M.M., Braver, T.S., Barch, D.M., Carter, C.S., Cohen, J.D., 2001. Conflict monitoring and cognitive control. *Psychol. Rev.* 108, 624–652.
- Brett, M., Anton, J.L., Valabregue, R., Poline, J.B., 2002. Region of interest analysis using an SPM toolbox [abstract]. Presented at the 8th International Conference on Functional Mapping of the Human Brain, June 2–6, 2002, Sendai, Japan. Available on CD-ROM in NeuroImage. Vol 16.
- Bush, G., Luu, P., Posner, M.I., 2000. Cognitive and emotional influences in anterior cingulate cortex. *Trends Cogn. Sci.* 4, 215–222.

- Carter, C.S., Mintun, M., Nichols, T., Cohen, J.D., 1997. Anterior cingulate gyrus dysfunction and selective attention deficits in schizophrenia: [^{15}O]H $_2\text{O}$ PET study during single-trial Stroop task performance. *Am. J. Psychiatry* 154, 1670–1675.
- Carter, C.S., MacDonald III, A.W., Ross, L.L., Stenger, V.A., 2001. Anterior cingulate cortex activity and impaired self-monitoring of performance in patients with schizophrenia: an event-related fMRI study. *Am. J. Psychiatry* 158, 1423–1428.
- Crespo-Facorro, B., Paradiso, S., Andreasen, N.C., O'Leary, D.S., Watkins, G.L., Boles Ponto, L.L., Hichwa, R.D., 1999. Recalling word lists reveals "cognitive dysmetria" in schizophrenia: a positron emission tomography study. *Am. J. Psychiatry* 156, 386–392.
- Crow, T.J., 1997. Schizophrenia as failure of hemispheric dominance for language. *Trends Neurosci.* 20, 339–343.
- Dehaene, S., Artiges, E., Naccache, L., Martelli, C., Viard, A., Schurhoff, F., Recasens, C., Martinot, M.L., Leboyer, M., Martinot, J.L., 2003. Conscious and subliminal conflicts in normal subjects and patients with schizophrenia: the role of the anterior cingulate. *Proc. Natl. Acad. Sci. U. S. A.* 100, 13722–13727.
- Fletcher, P., McKenna, P.J., Friston, K.J., Frith, C.D., Dolan, R.J., 1999. Abnormal cingulate modulation of fronto-temporal connectivity in schizophrenia. *NeuroImage* 9, 337–342.
- Friston, K.J., Holmes, A.P., Price, C.J., Buchel, C., Worsley, K.J., 1999. Multisubject fMRI studies and conjunction analyses. *NeuroImage* 10, 385–396.
- Haznedar, M.M., Buchsbaum, M.S., Hazlett, E.A., Shihabuddin, L., New, A., Siever, L.J., 2004. Cingulate gyrus volume and metabolism in the schizophrenia spectrum. *Schizophr. Res.* 71, 249–262.
- Heckers, S., Weiss, A.P., Deckersbach, T., Goff, D.C., Morecraft, R.J., Bush, G., 2004. Anterior cingulate cortex activation during cognitive interference in schizophrenia. *Am. J. Psychiatry* 161, 707–715.
- Hofer, A., Weiss, E.M., Golaszewski, S.M., Siedentopf, C.M., Brinkhoff, C., Kremser, C., Felber, S., Fleischhacker, W.W., 2003. Neural correlates of episodic encoding and recognition of words in unmedicated patients during an acute episode of schizophrenia: a functional MRI study. *Am. J. Psychiatry* 160, 1802–1808.
- Kerns, J.G., Cohen, J.D., Macdonald III, A.W., Johnson, M.K., Stenger, V.A., Aizenstein, H., Carter, C.S., 2005. Decreased conflict- and error-related activity in the anterior cingulate cortex in subjects with schizophrenia. *Am. J. Psychiatry* 162, 1833–1839.
- Kim, J.J., Kwon, J.S., Park, H.J., Youn, T., Kang do, H., Kim, M.S., Lee, D.S., Lee, M.C., 2003. Functional disconnection between the prefrontal and parietal cortices during working memory processing in schizophrenia: a [^{15}O]H $_2\text{O}$ PET study. *Am. J. Psychiatry* 160, 919–923.
- Le Provost, J.B., Bartres-Faz, D., Paillere-Martinot, M.L., Artiges, E., Pappata, S., Recasens, C., Perez-Gomez, M., Bernardo, M., Baeza, I., Bayle, F., Martinot, J.L., 2003. Paracingulate sulcus morphology in men with early-onset schizophrenia. *Br. J. Psychiatry* 182, 228–232.
- Morey, R.A., Inan, S., Mitchell, T.V., Perkins, D.O., Lieberman, J.A., Belger, A., 2005. Imaging frontostriatal function in ultra-high-risk, early, and chronic schizophrenia during executive processing. *Arch. Gen. Psychiatry* 62, 254–262.
- Nahas, Z., George, M.S., Horner, M.D., Markowitz, J.S., Li, X., Lorberbaum, J.P., Owens, S.D., McGurk, S., DeVane, L., Risch, S.C., 2003. Augmenting atypical antipsychotics with a cognitive enhancer (donepezil) improves regional brain activity in schizophrenia patients: a pilot double-blind placebo controlled BOLD fMRI study. *Neurocase* 9, 274–282.
- Nohara, S., Suzuki, M., Kurachi, M., Yamashita, I., Matsui, M., Seto, H., Saitoh, O., 2000. Neural correlates of memory organization deficits in schizophrenia. A single photon emission computed tomography study with $^{99\text{m}}\text{Tc}$ -ethyl-cysteinate dimer during a verbal learning task. *Schizophr. Res.* 42, 209–222.
- Ono, M., Kubik, S., Abernathy, C.D., 1990. Atlas of the Cerebral Sulci. Thieme Medical Publishers, Inc., Stuttgart.
- Sharma, T., 2003. Insights and treatment options for psychiatric disorders guided by functional MRI. *J. Clin. Invest.* 112, 10–18.
- Sommer, I.E., Ramsey, N.F., Kahn, R.S., 2001. Language lateralization in schizophrenia, an fMRI study. *Schizophr. Res.* 52, 57–67.
- Spence, S.A., Liddle, P.F., Stefan, M.D., Hellewell, J.S., Sharma, T., Friston, K.J., Hirsch, S.R., Frith, C.D., Murray, R.M., Deakin, J.F., Grasby, P.M., 2000. Functional anatomy of verbal fluency in people with schizophrenia and those at genetic risk. Focal dysfunction and distributed disconnectivity reappraised. *Br. J. Psychiatry* 176, 52–60.
- Van Essen, D.C., 1997. A tension-based theory of morphogenesis and compact wiring in the central nervous system. *Nature* 385, 313–318.
- Wiegand, L.C., Warfield, S.K., Levitt, J.J., Hirayasu, Y., Salisbury, D.F., Heckers, S., Bouix, S., Schwartz, D., Spencer, M., Dickey, C.C., Kikinis, R., Jolesz, F.A., McCarley, R.W., Shenton, M.E., 2005. An in vivo MRI study of prefrontal cortical complexity in first-episode psychosis. *Am. J. Psychiatry* 162, 65–70.
- Yucel, M., Stuart, G.W., Maruff, P., Velakoulis, D., Crowe, S.F., Savage, G., Pantelis, C., 2001. Hemispheric and gender-related differences in the gross morphology of the anterior cingulate/paracingulate cortex in normal volunteers: an MRI morphometric study. *Cereb. Cortex* 11, 17–25.
- Yucel, M., Pantelis, C., Stuart, G.W., Wood, S.J., Maruff, P., Velakoulis, D., Pipingas, A., Crowe, S.F., Tochon-Danguy, H.J., Egan, G.F., 2002a. Anterior cingulate activation during Stroop task performance: a PET to MRI coregistration study of individual patients with schizophrenia. *Am. J. Psychiatry* 159, 251–254.
- Yucel, M., Stuart, G.W., Maruff, P., Wood, S.J., Savage, G.R., Smith, D.J., Crowe, S.F., Copolov, D.L., Velakoulis, D., Pantelis, C., 2002b. Paracingulate morphologic differences in males with established schizophrenia: a magnetic resonance imaging morphometric study. *Biol. Psychiatry* 52, 15–23.
- Yucel, M., Wood, S.J., Fornito, A., Riffkin, J., Velakoulis, D., Pantelis, C., 2003. Anterior cingulate dysfunction: implications for psychiatric disorders? *J. Psychiatry Neurosci.* 28, 350–354.